



**PATIENT**

Rockie Hamilton

**SPECIES**

Canine

**BREED**

Pitbull

**SEX**

Male Neutered

**AGE**

8 years

**WEIGHT**

85 lbs

**INTERPRETED BY**

Maggie Machen  
Lamy, DVM, DACVIM  
(Cardiology)

**IMAGING PERFORMED BY**

Kim Liedberg

**HOSPITAL NAME**

SVS Imaging WI

**REFERRING VET**

Dr. Baum

**INVOICE**

24159

**DATE**

5/11/22

**PRESENTING CLINICAL SIGNS**

History: Hx of MCT removal that has reoccurred. Assess prior to anesthesia. Cardiomegaly on CXR. No Murmur or arrhythmia noted on exam. He has been on a grain free diet since he was 2 y/o. Abnormal PE/Chem/CBC/UA Results: ProBNP 2163.9

**RADIOGRAPHIC FINDINGS** \*NOTE: Images submitted for supplemental cardiac information only. Mild cardiomegaly. No obvious evidence of CHF.

**ELECTROCARDIOGRAPHIC FINDINGS** \*Note: Single lead ECGs are evaluated as a rhythm strip. Morphology/MEA cannot be definitively commented on. A single lead ECG is available; 25mm/s, 10mm/mV. The average heart rate is 90bpm (range 51-120bpm). The rhythm is sinus in origin, with a p for every QRS complex and vice versa. The P and QRS morphologies are positive. No ectopic beats, pauses or other dysrhythmias observed. ECG diagnosis: Normal sinus rhythm with respiratory variation.

**ECHOCARDIOGRAM FINDINGS**

2D, m-mode, color flow and doppler imaging is available. Mild diffuse thickening of mitral valve leaflets with no prolapse into the left atrial lumen. Mild eccentric mitral regurgitation with mild left atrial dilation. Normal LV diameter with increased sphericity. Borderline myocardial function. The tricuspid valve appears normal with trace tricuspid regurgitation. Normal velocity. Normal right atrial and ventricular diameter and morphology indicating no overt evidence of pulmonary arterial hypertension. The pulmonic and aortic valves are normal in morphology and mobility. Normal pulmonic and aortic outflow velocities with laminar flow. No obvious aortic or pulmonic insufficiency. No pericardial or pleural effusion noted. No obvious cardiac masses.

**CARDIAC CHART**

CANINE CARDIAC PARAMETERS	MR VMAX (m/s)	TR VMAX (m/s)	LA/AO (Boon method)	LA/AO (Heart Base; Swe)	FS (%)	EF (%)	EPSS (cm)
NORMAL PARAMETER	4.5-5.5	<2.7	1.3	<1.6	28-40	40-100	<0.6
PATIENT	NM	2.5	NM	1.4	26	50	1.1
CANINE CARDIAC PARAMETERS	HR (BPM)	AV VMAX (m/s)	PV MAX (m/s)	BODY WEIGHT (kg)	LA 2D short axis Base view (cm)	LVIDd Avg; 2D and m-mode short axis (cm)	LVIDs Avg; 2D and m-mode short axis (cm)
NORMAL PARAMETER	50-100	0.7-1.7	0.7-1.6	BELOW	BELOW	BELOW	BELOW
PATIENT	60	1.8	1.3	38.6	2.8	5.0	3.8
*Normal chamber parameters expressed as a mean value (SD)				3	1.27 (5.3)	2.46 (2.46)	1.36 (5.5)
<b>BODY WEIGHT DEPENDENT PARAMETERS</b>				5	1.40 (4.5)	2.74 (5.2)	1.60 (4.7)
*Note: All measurements based upon multi-modal images and methods. An average value is reported.				10	1.50 (3.8)	3.27 (3.5)	2.06 (3.1)
				15	1.83 (2.0)	3.71 (2.4)	2.43 (2.1)
				20	2.02 (1.9)	4.14 (2.2)	2.80 (2.0)
				25	2.18 (2.4)	4.48 (2.9)	3.10 (2.5)
				30	2.33 (3.3)	4.83 (3.9)	3.39 (3.4)
				35	2.48 (4.3)	5.17 (5.0)	3.69 (4.5)
				40	2.62 (5.2)	5.48 (6.1)	3.96 (5.4)
				50	2.88 (7.1)	6.07 (8.3)	4.46 (7.4)

Adapted from June Boon, Veterinary Echocardiography, 1998  
Rishniw M and Hollis NE, J Vet Intern Med 2000; 14:429-435  
Hansson et al, Vet Rad and Ultrasound 2002  
Bonagura et al. Echocardiography: principles of interpretation, Vet Clin North Am 15:1177, 1995



## PATIENT

Rockie Hamilton

## SPECIES

Canine

## BREED

Pitbull

## SEX

Male Neutered

## AGE

8 years

## WEIGHT

85 lbs

## INTERPRETED BY

Maggie Machen  
Lamy, DVM, DACVIM  
(Cardiology)

## IMAGING PERFORMED BY

Kim Liedberg

## HOSPITAL NAME

SVS Imaging WI

## REFERRING VET

Dr. Baum

## INVOICE

24159

## DATE

5/11/22

## INTERPRETATION OF THE FINDINGS & FURTHER RECOMMENDATIONS

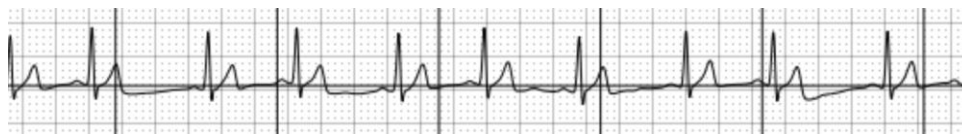
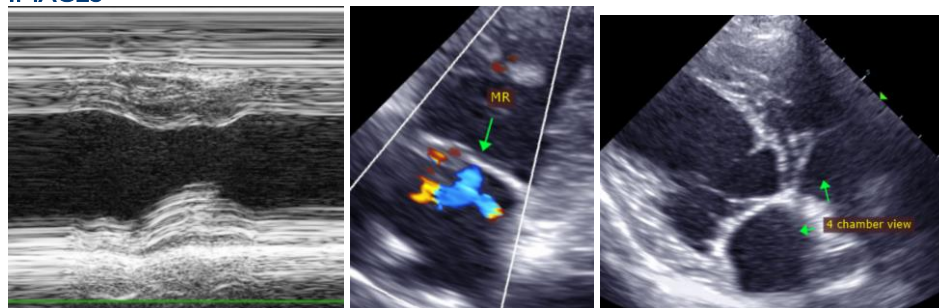
Chronic degenerative valve disease causing mild mitral and trace tricuspid regurgitation. Lack of significant left atrial enlargement indicates the current risk for complication is low. The LV function is borderline with a spherical appearance, which may be a normal variant or may reflect mild changes due to a non-traditional diet. A diet change is recommended. No concurrent issues such as pulmonary hypertension are noted in this study. The ECG is unremarkable with a respiratory sinus arrhythmia.

In an asymptomatic dog with no significant left atrial enlargement, no cardiac medications are clearly indicated. Assessment of progression in the future will help predict long term prognosis, which is highly variable at this stage (B1). Omega fatty acid supplementation and mild salt restriction may be of some long-term benefit. Monitor for development of a cough, labored breathing, exercise intolerance or collapse episodes.

Anesthetic risk is considered mild if needed. Cardiac protective drug choices (opioid/benzodiazepine premedication, propofol or alfaxalone induction, isoflurane gas) are recommended. Pre-oxygenate for 5-10 minutes prior to induction. Monitor for arrhythmias, hypotension, and hypoxia both intra and post-operatively and intervene as necessary. Mild IV fluid restriction is recommended to avoid fluid overload. Avoid heart rate stimulating drugs such as atropine unless clinically indicated.

Recommend conservative monitoring with a recheck echocardiogram in 6 months, sooner if any development of clinical signs.

## IMAGES



The information and recommendations provided are based on the images presented by the referring veterinarian. No evaluation can be communicated regarding pathology that was not visible in the image/video clips provided.

Thank you for this referral. If the clinical or image interpretation does not parallel your findings or if I can be of any further assistance, please contact me.

Maggie Machen Lamy, DVM  
Diplomate of the American College of Veterinary Internal Medicine (Cardiology)  
info@sonopath.com